

AVIAN OPHTHALMIC EXAM

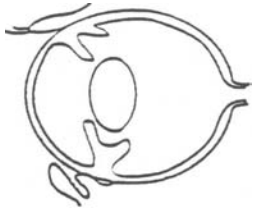
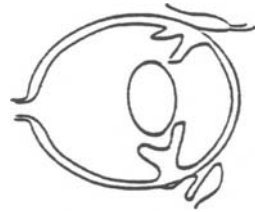
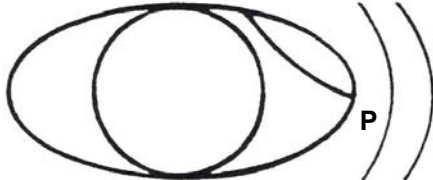
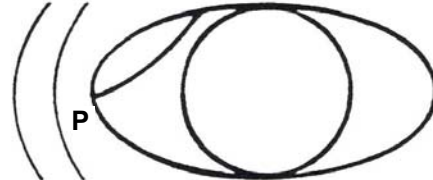


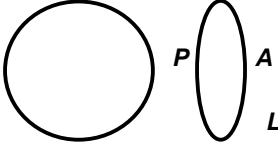
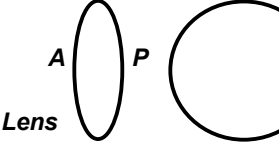


THE RAPTOR CENTER
UNIVERSITY OF MINNESOTA

Date: _____ Species: _____

Weight: _____ Case Number: _____

History: _____

Current Medications: _____

	OD	OS		
PLR				
Direct	___	___		
Palpebral	___	___		
Corneal	___	___		
Dazzle	___	___		
STT (mm/min)	___	___		
Fluorescein	___	___		
IOP (mmHg)	___	___		
				
			Cornea	Cornea
				
			Iris	Iris
				
			Lens	Lens
				
			Fundus	Fundus

Diagnosis: _____

Treatment: _____

Signature: _____ Date: _____